

## A Novel Method of Using Mri in Diagnosing Masseteric Muscle Cavernous Haemangioma in A Case Series: A Original Research Article

E.Elavarasi<sup>1</sup>, T.V.Ulaganathan<sup>2</sup>, V.Sadesh Kannan<sup>3</sup>, R.Priyadarshini<sup>4</sup>, S.P.Indra Kumar<sup>5</sup>, E.Gayathri Priyadarshini<sup>6</sup>

<sup>1</sup>(Department Of Oral & Maxillofacial Radiology & Surgery, Adiparasakthi Dental College & Hospital, Tamilnadu Dr.MGR Medical University, Melmaruvathur)

<sup>2,3,4,5</sup>(R.M.O, Arupadaiveedu Medical College & Hospital, Vinayaga Mission University, Puducherry, India)

<sup>6</sup>(Senior Lecturer, Indiragandhi Institute Of Dental Sciences, Sri Balaji Vidyapeeth University, Puducherry)

---

**Abstract:** Intramuscular cavernous Haemangiomas represent less than 1% of all haemangiomas and consist of benign proliferations of blood vessels. Typical presentation is an enlarging painful soft-tissue mass without cutaneous changes. We diagnosed a series of 5 cases of cavernous haemangioma of the masseteric muscle presenting as an asymptomatic unilateral swelling. The rarity of a cavernous haemangioma in such a location with its presentation as a unilateral swelling without cutaneous changes made the cases unique and the MRI proves to be the novel method to arrive at a definitive diagnosis.

---

### I. Introduction

Haemangiomas are benign tumours that are characterized by a rapid growth phase with endothelial cell proliferations followed by gradual involution. Cavernous haemangiomas occur at a deeper plane and have been described in most of the head and neck locations in a variety of presentation. Very few cases of Cavernous haemangioma of the Intra-masseteric muscle have been reported. This case of cavernous haemangioma is described because of its uncommon location and its confusing clinical presentation as a unilateral soft tissue swelling of the buccal mucosa.

### II. Materials

There were 5 cases of similar Intra-Masseteric Muscle Cavernous Hemangiomas came to our OPD (Out-patient Department) at Arupadaiveedu Medical College & Hospital between 2015 & 2016, Male female ratio is 1:5, in which 3 on left side and 2 on right side with an age between 16 to 32.

### III. Methods

All cases having ill-defined diffuse swelling in the pre-auricular region with a positive “Turkey Wattle Sign”, were subjected for investigations like Orthopantomogram (OPG), USG (Ultra Sonography) colour Doppler, FNAC (Fine Needle Aspiration Cytology), and MRI (Magnetic Resonance Imaging).

Here we are sampling a 20 years old female patient with complete records in 5 of the patients reported to our OPD, She came with the complaints of swelling in the left cheek of two months duration. She first noticed the swelling while washing her face. Swelling gradually increased in size, becoming more pronounced during mastication and while waking up in morning. She was more concern about her aesthetics and presented in our OPD for a consultation.

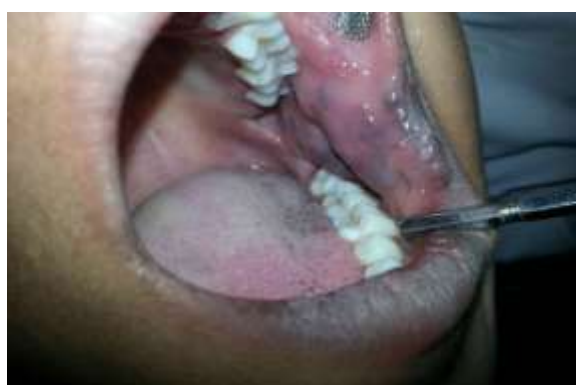The clinical examination revealed facial asymmetry seen due to diffuse swelling seen in the left middle one third of the face, size of 3x5 cm approx, borders are ill defined, which extends superiorly – 1cm away from the left zygoma region, Inferiorly – 2cm short of the inferior border of mandible, Medially – 1cm away from left ala of nose, Laterally – 2cm short of left preauricular region. There was no compressibility and the overlying skin was normal with no visible pulsation (Fig:1). The turkey wattle sign was elicited and swelling was soft in consistency (Fig:2). The Intraoral examination reveals the presence of patchy bluish discoloration in the left buccal mucosa (Fig:3), extending from left commissure of the lip to posterior buccal mucosa which was soft in consistency and tender. The case was provisionally diagnosed as vascular malformation. The differential diagnosis considered were Hemangioma, venous varix, and angiosarcoma.



**Fig 1:** Frontal view



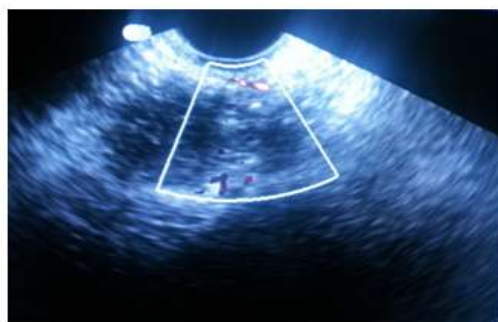**Fig 2:** Turkey Wattle Sign was elicited on left side



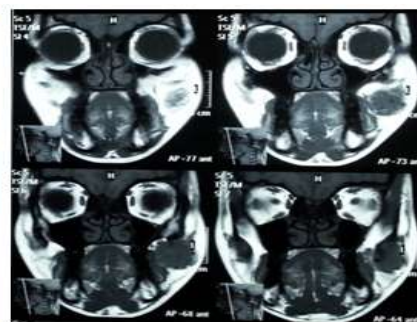
**Figure 2:** Intra-oral Bluish Decolourisation

OPG reveals no positive findings nor a bony lesion. USG of left cheek reveals a fairly large complex heterogenous cystic mass lesion with multiple internal calcified nodules seen in the left cheek buccal space just anterior to the masseteric muscle and ramus of the mandible measure 2.3X2 cm. Possibility of vascular lesion should be ruled out using further investigations like FNAC, Color doppler, & MRI scan. USG color doppler scan reveals ill defined mixed echogenic foci with two hyperechoic internal echoes of size 2x2.3x1.3cm with vascular uptake, in the fat plane suggestion of AV malformation (Fig: 4). MRI Contrast reveals well defined homogenous lesion of size 28.3x25.7mm seen in left cheek anterior to masseter muscle extending medial to it with evidence of flow void noted with in it, lesion appears hypointense in T1, hyperintense in T2 not suppressed in STIR with no Extra-oral blooming in gradient sequence. After giving I.V contrast the lesion shows heterogenous early patchy central enhancement fills the lesion homogenous in delayed post contrast image suggestive of haemangioma of left cheek (Fig:5, Fig:6, Fig:7). All 5 cases were showed a similar result in spite of side, size, and shape, which denotes that MRI is the novel method for diagnosing Intra-Masseteric cavernous Haemangiomas.

FNAC revealed blood smears show only blood component and numerous hemosiderin laden macrophages suggestive of vascular lesion.



**Fig 4:** USG colour Doppler



**Fig 5:** MRI contrast- Axial view

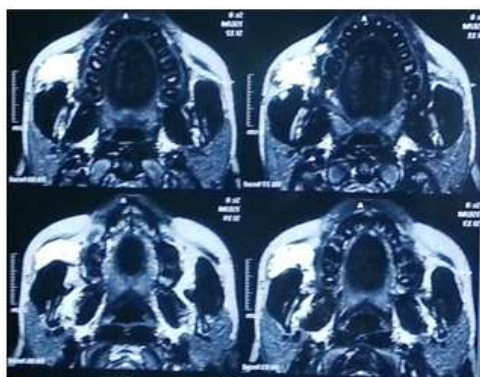


Fig 6: MRI contrast- Coronal view

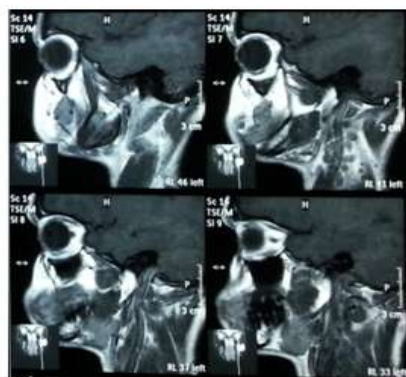


Fig 7: MRI contrast- Sagittal View

#### IV. Discussion

In 1843, Liston<sup>1</sup> was the first to report a case of intramuscular cavernous haemangioma naming it as an “erectile tumour”. Haemangioma are benign proliferative vascular lesions characterized by increased endothelial cell turnover. These tumours usually appear after birth, grow rapidly, and involute over the years. Within the spectrum of vascular lesions, intramuscular haemangioma are very rare, accounting for less than 1% of all haemangioma, and the masseter muscle is the most frequent muscle, accounting for 5% of all intramuscular haemangioma. The trapezius, periorbital, sternocleidomastoid, and temporalis muscles follow the masseter muscle in frequency<sup>2</sup>. These tumours present as gradually enlarging mass lesions with duration often less than a year<sup>3</sup>. In the present case the tumor appeared to be arising from the buccinator and masseter muscle. Intra muscular hemangiomas are considered hamartomatous lesions and thought to arise from abnormal embryonic rests. Based on the vessel size intramuscular haemangiomas can be classified into capillary, cavernous and mixed with capillary form being the most common. A possible hormonal role in the growth of intramuscular haemangioma was speculated, but no specific data was available to irrefutably prove this hypothesis. They are usually asymptomatic until a growth spurt occurs, at which time pain occurs in about 50% of cases. A palpable, fluctuant or firm mass is present in up to 98% of case.

Allen & Enzinger classified them as large vessel [ $>140$  mm in diameter] small vessel [ $<140$  mm in diameter] and mixed vessel types. They correspond to cavernous, capillary, and mixed type respectively<sup>4</sup>. This classification is useful and correlates well with clinical presentation and recurrence rates. The capillary type of haemangioma occurred more frequently in the head and neck region. The highly cellular nature of many capillary haemangiomas may explain the lack of clinical signs usually associated with vascular lesions, thus rendering pre-op diagnosis difficult. The cavernous and mixed types occurred more frequently in the trunk and lower limbs. The mixed type had the greatest tendency for local recurrence [28%].

These tumours present as gradually enlarging mass lesions with duration often less than a year. Accurate preoperative diagnosis has been reported in less than 8% of cases in view of its intramuscular location and the overlying parotid. Bruits, thrills, compressibility are often absent unlike in other vascular malformations. The most common clinical presentation is a mass with associated pain symptoms in 50 to 60% of cases. There are usually no skin changes. Clenching the teeth could make the lesion to become more firm and fixed. A variety of tumours can be confused clinically with an IMH. Most of them are often mistaken for salivary neoplasms & the differential diagnosis include cysts, lymphangiomas, rhabdomyosarcomas, masseteric hypertrophy, and schwannomas<sup>5</sup>.

The diagnosis of intramuscular haemangioma requires a high index of suspicion. whenever a mass of soft tissue density is encountered in the region of skeletal muscle in a young adult, haemangioma should be considered in the differential diagnosis. Most haemangioma are recognized clinically and does not require any investigation or any treatment as they will subside spontaneously. However, imaging is needed in cases of deep haemangioma with normal overlying skin, cases of clinically atypical soft-tissue masses, when the evaluation of extension of obvious haemangioma is necessary, cases of alarming haemangioma and for guiding therapy. Sonography is the first-line imaging procedure for patients with soft tissue swellings. Colour Doppler sonography is especially useful to demonstrate the vascular structures in and around the masseter muscle, and has the potential of being used to evaluate the pathological changes. Haemangioma could be distinguished from other soft tissue lesions by the features of abundant vascularity and high blood flow velocity. MRI is more reliable in detecting and delineating deep situated and large intramuscular haemangioma, and it gives the most diagnostic information<sup>6,7</sup>.

Although some authors believe that FNAC is commonly non-diagnostic, showing the presence of a purely bloody specimen may be considered strongly suggestive for intramuscular haemangioma as seen in our case. FNAC should also be performed to aid in the exclusion of other soft tissue tumours. Management of intramuscular haemangioma should be individualized according to the size and anatomic accessibility of the tumour, its growth rate, age of the patient and cosmetic and functional considerations. If indicated, complete surgical resection is preferred, but local recurrence rates have been reported as 18% and 19% in two different studies. Alternatives to surgical excision of intramuscular haemangioma are embolisation and radiotherapy, with the treatment of choice being decided by the site of the lesion. But it has been reported that modalities such as embolisation, injection of sclerosants and radiotherapy have had limited success<sup>8</sup>.

## **V. Conclusion**

Intra-masseteric cavernous haemangiomas may start to grow in childhood and should be considered in the differential diagnosis of isolated muscle enlargement. Colour Doppler sonography should be considered as first line of imaging in all soft tissue swellings but MRI is the novel method for in diagnostic workup and the treatment of choice should be individualized in view of the clinical status of the patient. For all these patients all treatment modalities available and prognosis were explained in detail and given references to higher center for an advance diagnostic aid and further management.

## **Acknowledgement**

- 1) Dr.A.S.Ganesan, Honourable Chancellor, Vinayaga mission University, Kilpauk, Chennai, for his kind support,
- 2) Prof.Dr.P.Anusuya, Dean, Arupadaivedu Medical College & Hospital, Puducherry, for his eminent guidance, &
- 3) Prof.Dr.Maharajan, Medical Superintendent, Arupadaivedu Medical College & Hospital, Puducherry, for his eminent guidance,

## **References**

- [1]. Liston R. Case of erectile tumour in the popliteal space: removal. *Med Chir Trans* 1843;26:120-32.
- [2]. Fatma Sule Afsar, Ergun Oziz2, Yalcin Hamdioglu. Intramuscular haemangioma of the masseter muscle in a 9-year-old girl Case report. *Acta Angiol.*2007 Vol. 13, No. 1, pp. 42-46
- [3]. C D Narayanan, Preeth Prakash and C K Dhanasekaran. Intramuscular hemangioma of the masseter muscle: a case report. *Cases Journal* 2009, 2:7459
- [4]. Allen PW, Enzinger FM: Hemangioma of skeletal muscle; an analysis of 89 cases. *Cancer* 1972, 29:8-22.
- [5]. Wolf GT, Daniel F, Krause CJ, Kaufman RS: Intramuscular Hemangioma of the head and neck. *Laryngoscope* 1985, 95:210-213.
- [6]. Peter C.Buetow et al. Radiologic appearance of Intramuscular Hemangioma with emphasis on MRI Imaging. *AJR* 154: 563 – 567, March 1990.
- [7]. Tashika Kushraj, \*Laxmikanth Chatra, \*Prashanth Shenai. cavernous hemangioma of the buccinator muscle- mri features. *Pacific Journal of Medical Sciences*: Vol. 12. No 2, December 2013
- [8]. Text Book Of Oral Medicine – Burket’s 11<sup>th</sup> Edition